

Patient **Doe, John**

Pathology Report

Social 123-45-6789

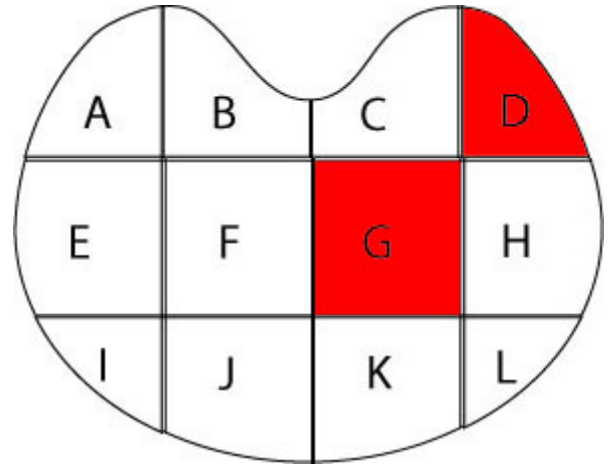
DOB 1/1/1945 Gender M

Med ID 12345

Diagnosis

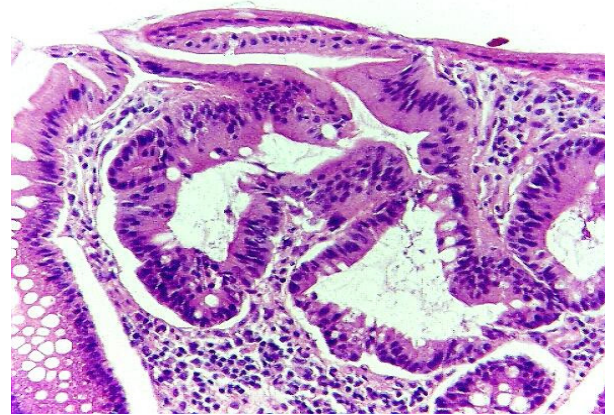
- A. Prostate - Left Lateral Base
FLAT HYPERPLAIA
- B. Prostate - Left Base
BENIGN PROSTATE TISSUE
- C. Prostate - Right Base
BENIGN PROSTATE TISSUE
- D. Prostate - Right Lateral Base
ADENOCARCINOMA, GLEASON GRADE GLEASON SCORE % OF THE BIOPSY MATERIAL.
- E. Prostate - Left Lateral Mid
BENIGN PROSTATE TISSUE
- F. Prostate - Left Mid
BENIGN PROSTATE TISSUE
- G. Prostate - Right Mid
ADENOCARCINOMA, GLEASON GRADE GLEASON SCORE % OF THE BIOPSY MATERIAL.
- H. Prostate - Right Lateral Mid
HIGH GRADE PROSTATIC INTRAEPITHELIAL NEOPLASIA (HGPIN).
- I. Prostate - Left Lateral Apex
BENIGN PROSTATE TISSUE
- J. Prostate - Left Apex
BENIGN PROSTATE TISSUE
- K. Prostate - Right Apex
BENIGN PROSTATE TISSUE
- L. Prostate - Right Lateral Apex
BENIGN PROSTATE TISSUE

12 Core Biopsy Diagnostic Map



Images

Specimen E



Microscopic Description

- Specimen A.. 1. This prostatic tissue shows malignant change of the gl: diagnosis. Perineural extension is not seen.
- Specimen B.. 1. This prostatic tissue shows malignant change of the gl: diagnosis. Perineural extension is not seen.
- Specimen C.. 1. This prostatic tissue shows malignant change of the gl: diagnosis. Perineural extension is not seen.



IOP Urology

123 Main St Toledo, OH 43623
(419) 555-5555
Fax (419) 555-1234

S09-1

Date Collected 2/13/2009
Date Received 2/13/2009
Case Date 2/13/2009
Physician Bernie Ness
Ordering Location IOP Urology

Patient **Doe, John**

Pathology Report

Social 123-45-6789

DOB 1/1/1945 Gender M

Med ID 12345

Specimen D.. 1. This prostatic tissue shows malignant change of the gl
the diagnosis. Perineural extension is not seen.
Specimen E.. 1. This prostatic tissue shows malignant change of the gl
diagnosis. Perineural extension is not seen.
Specimen F.. 1. This prostatic tissue shows malignant change of the gl
diagnosis. Perineural extension is not seen.
Specimen G.. 1. This prostatic tissue shows malignant change of the gl
the diagnosis. Perineural extension is not seen.
Specimen H.. 1. This prostatic tissue shows malignant change of the gl
the diagnosis. Perineural extension is not seen.
Specimen I.. 1. This prostatic tissue shows malignant change of the gla
diagnosis. Perineural extension is not seen.
Specimen J.. 1. This prostatic tissue shows malignant change of the gla
diagnosis. Perineural extension is not seen.
Specimen K.. 1. This prostatic tissue shows malignant change of the gl
diagnosis. Perineural extension is not seen.
Specimen L.. 1. This prostatic tissue shows malignant change of the gla
diagnosis. Perineural extension is not seen.

Gross Descriptions

A.	Prostate	No Of Fragments 1	Shape Circular
	Location Left Lateral Base		Color White/Tan
	From (cm)		
B.	Prostate	No Of Fragments 1	Shape Circular
	Location Left Base		Color White/Tan
	From (cm)		
C.	Prostate	No Of Fragments 1	Shape Circular
	Location Right Base		Color White/Tan
	From (cm)		
D.	Prostate	No Of Fragments 1	Shape Circular
	Location Right Lateral Base		Color White/Tan
	From (cm)		
E.	Prostate	No Of Fragments 1	Shape Circular
	Location Left Lateral Mid		Color White/Tan
	From (cm)		
F.	Prostate	No Of Fragments 1	Shape Circular
	Location Left Mid		Color White/Tan
	From (cm)		

CLIA 12345

COLA 12345



IOP Urology

123 Main St Toledo, OH 43623
(419) 555-5555
Fax (419) 555-1234

S09-1

Date Collected 2/13/2009
Date Received 2/13/2009
Case Date 2/13/2009
Physician Bernie Ness
Ordering Location IOP Urology

Pathology Report

Patient **Doe, John**
Social 123-45-6789
DOB 1/1/1945 Gender M
Med ID 12345

G.	Prostate	No Of Fragments 1	Shape Circular
	Location Right Mid		Color White/Tan
	From (cm)		
H.	Prostate	No Of Fragments 1	Shape Circular
	Location Right Lateral Mid		Color White/Tan
	From (cm)		
I.	Prostate	No Of Fragments 1	Shape Circular
	Location Left Lateral Apex		Color White/Tan
	From (cm)		
J.	Prostate	No Of Fragments 1	Shape Circular
	Location Left Apex		Color White
	From (cm)		
K.	Prostate	No Of Fragments 1	Shape Circular
	Location Right Apex		Color White
	From (cm)		
L.	Prostate	No Of Fragments 1	Shape Circular
	Location Right Lateral Apex		Color White
	From (cm)		

CPT Code	Quantity
88305	12

Electronically Signed Ou

2/13/2009 4:12:35 PM BY Kevorkian, Jack

CLIA 12345
COLA 12345